



The American College of
Obstetricians and Gynecologists
WOMEN'S HEALTH CARE PHYSICIANS

PRACTICE BULLETIN

CLINICAL MANAGEMENT GUIDELINES FOR OBSTETRICIAN—GYNECOLOGISTS

Number 128, July 2012

(Reaffirmed 2016)

Committee on Practice Bulletins—Gynecology. This Practice Bulletin was developed by the Committee on Practice Bulletins—Gynecology with the assistance of Micah J. Hill, DO, Eric D Levens, MD, and Alan H. DeCherney, MD. The information is designed to aid practitioners in making decisions about appropriate obstetric and gynecologic care. These guidelines should not be construed as dictating an exclusive course of treatment or procedure. Variations in practice may be warranted based on the needs of the individual patient, resources, and limitations unique to the institution or type of practice.

PDF Format

Diagnosis of Abnormal Uterine Bleeding in Reproductive-Aged Women

Menstrual flow outside of normal volume, duration, regularity, or frequency is considered abnormal uterine bleeding (AUB). One third of outpatient visits to the gynecologist are for AUB, and it accounts for more than 70% of all gynecologic consults in the perimenopausal and postmenopausal years (1). Many new diagnostic modalities are available to assist the clinician in evaluating the woman with alterations in her normal menstrual patterns. The purpose of this document is to provide evidence-based management guidelines for the evaluation of the reproductive-aged patient with AUB. A secondary purpose is to introduce a new classification system for AUB. This document does not address pregnancy-related bleeding or postmenopausal bleeding.

Background

Definition and Nomenclature

The duration of normal menstrual flow is generally 5 days, and the normal menstrual cycle typically lasts between 21 days and 35 days. Descriptive terms that traditionally have been used to characterize abnormal menstrual bleeding patterns include menorrhagia, metrorrhagia, polymenorrhea, and oligomenorrhea. Menorrhagia, or heavy menstrual bleeding, is defined as menstrual blood loss greater than 80 mL (2). However, this definition is used for research purposes and, in practice, excessive blood loss should be based on the patient's perception. Metrorrhagia is defined as bleeding between periods.

Polymenorrhea is defined as bleeding that occurs more often than every 21 days, and oligomenorrhea is defined as bleeding that occurs less frequently than every 35 days.

In an effort to create a universally accepted system of nomenclature to describe uterine bleeding abnormalities in reproductive-aged women, a new classification system (polyp, adenomyosis, leiomyoma, malignancy and hyperplasia, coagulopathy, ovulatory dysfunction, endometrial, iatrogenic, and not yet classified), known by the acronym PALM–COEIN, was introduced in 2011 by the International Federation of Gynecology and Obstetrics (FIGO) (3). The American College of Obstetricians and Gynecologists supports the adoption of the PALM–COEIN nomenclature system developed by FIGO to standardize the terminology used to describe AUB.

The PALM–COEIN system classifies uterine bleeding abnormalities by bleeding pattern as well as by etiology. The overarching term AUB is paired with descriptive terms to denote bleeding patterns associated with AUB, such as heavy menstrual bleeding (instead of menorrhagia) and intermenstrual bleeding (instead of metrorrhagia). Abnormal uterine bleeding is further classified by one (or more) letter qualifiers that indicate its etiology or etiologies (Fig. 1). The term dysfunctional uterine bleeding—often used synonymously with AUB in the literature to indicate AUB for which there was no systemic or locally definable structural cause—is not part of the PALM–COEIN system, and discontinuation of its use is recommended (3).

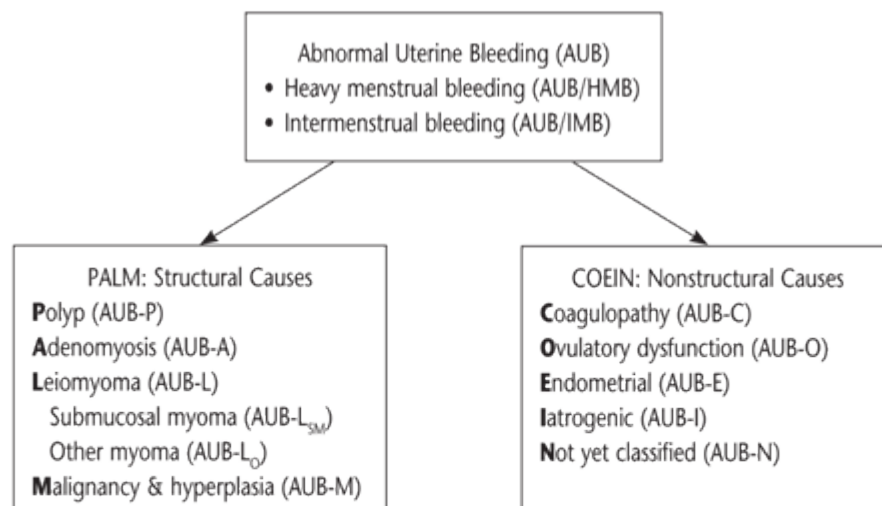


Fig. 1. Basic PALM–COEIN classification system for the causes of abnormal uterine bleeding in nonpregnant women of reproductive age. This system, approved by the International Federation of Gynecology and Obstetrics, uses the term AUB paired with descriptive terms that describe associated bleeding patterns (HMB or IMB), or a qualifying letter (or letters), or both to indicate its etiology (or etiologies). Modified from Munro MG, Critchley HO, Broder MS, Fraser IS. FIGO classification system (PALM–COEIN) for causes of abnormal uterine bleeding in nongravid women of reproductive age. FIGO Working Group on Menstrual Disorders. *Int J Gynaecol Obstet* 2011;113:3–13.

Pathophysiology

The most common causes of abnormal uterine bleeding include uterine pathologies (PALM–COEIN classifications are shown parenthetically), such as endometrial polyps (AUB-P), adenomyosis (AUB-A),

uterine leiomyomas (AUB-L), and endometrial hyperplasia or carcinoma (AUB-M). Other possible etiologies include systemic conditions, such as coagulopathies, both inherited (eg, von Willebrand disease) and acquired (AUB-C), and ovulatory dysfunction (AUB-O). Ovulatory AUB is more common than AUB that is related to ovulatory dysfunction (4).

Box 1. Clinical Screening for an Underlying Disorder of Hemostasis in the Patient With Excessive Menstrual Bleeding

Initial screening for an underlying disorder of hemostasis in patients with excessive menstrual bleeding should be structured by medical history (positive screen comprises any of the following):

*

Heavy menstrual bleeding since menarche

One of the following:

Postpartum hemorrhage

Surgery-related bleeding

Bleeding associated with dental work

Two or more of the following symptoms:

Bruising one to two times per month

Epistaxis one to two times per month

Frequent gum bleeding

Family history of bleeding symptoms

*Patients with a positive screen should be considered for further evaluation, including consultation with a hematologist and testing of von Willebrand factor and ristocetin cofactor.

Reprinted from Kouides PA, Conard J, Peyvandi F, Lukes A, Kadir R. Hemostasis and menstruation: appropriate investigation for underlying disorders of hemostasis in women with excessive menstrual bleeding. *Fertil Steril* 2005;84(5):1345–51.

Ovulatory dysfunction (AUB-O) is a spectrum of disorders that range from amenorrhea to irregular heavy menstrual periods. They are typically the result of an endocrinopathy, such as polycystic ovary syndrome (PCOS). In these cases of AUB, the mechanisms of abnormal bleeding are related to

unopposed estrogen. In ovulatory AUB the hypothalamic–pituitary–ovarian axis is intact and steroid hormone profiles are normal. Once regular menses has been established during adolescence, ovulatory AUB accounts for most cases (4). Mechanisms for ovulatory AUB include abnormal prostaglandin synthesis and receptor upregulation (5–7), increased local fibrinolytic activity (8), and increased tissue plasminogen activator activity (9).

Diagnosis

The evaluation of women with AUB includes a thorough medical history and physical examination, appropriate laboratory and imaging tests, and consideration of age-related factors (see the section “Age-Based Common Differential Diagnosis”).

Medical History and Physical Examination

A medical history should include questions about menstrual bleeding patterns, severity and pain associated with bleeding, and family history of AUB or other bleeding problems because up to 20% of women (at any age) presenting with heavy menstrual bleeding will have an underlying bleeding disorder (10–13). An initial screening for an underlying disorder of hemostasis should be performed (see Box 1). If a concern remains about a possible bleeding disorder, the National Heart, Lung, and Blood Institute management guidelines may be helpful (<http://www.nhlbi.nih.gov/guidelines/vwd/vwd.pdf>) (14, 15). The patient medical history also should include questions about the use of medications or herbal remedies that might cause AUB, such as warfarin, heparin, nonsteroidal antiinflammatory drugs, hormonal contraceptives, ginkgo, ginseng, and motherwort (16, 17).

General physical findings of note include excessive weight, signs of PCOS (eg, hirsutism and acne), signs of thyroid disease (eg, thyroid nodule), and signs of insulin resistance (eg, acanthosis nigricans on the neck). Physical examination findings suggestive of a bleeding disorder include petechiae, ecchymoses, skin pallor, or swollen joints, although absence of these signs does not exclude the possibility of an underlying bleeding condition (18–20). A pelvic examination also should be performed as part of the physical examination, and in adults, this should include speculum and bimanual examination. A speculum examination should be performed to assess for cervical or vaginal lesions, with appropriate tissue sampling when abnormalities are noted. A bimanual examination should be performed to assess the size and contour of the uterus.

Box 2. Diagnostic Evaluation of Abnormal Uterine Bleeding

Medical History

Age of menarche and menopause

Menstrual bleeding patterns

Severity of bleeding (clots or flooding)

Pain (severity and treatment)

Medical conditions

Surgical history

Use of medications

Symptoms and signs of possible hemostatic disorder

Physical Examination

General physical

Pelvic Examination

—External

—Speculum with Pap test, if needed*

—Bimanual

Laboratory Tests

Pregnancy test (blood or urine)

Complete blood count

Targeted screening for bleeding disorders (when indicated)[†]

Thyroid-stimulating hormone level

Chlamydia trachomatis

Available Diagnostic or Imaging Tests (when indicated)

Saline infusion sonohysterography

Transvaginal ultrasonography

Magnetic resonance imaging

Hysteroscopy

Available Tissue Sampling Methods (when indicated)

Office endometrial biopsy

Hysteroscopy directed endometrial sampling (office or

operating room)

*For the nonadolescent patient only.

†Including a coagulation panel for adolescents and adult patients with suspected bleeding disorders.

Laboratory Testing

Laboratory assessment for AUB should include a pregnancy test, complete blood count (CBC); measurement of thyroid-stimulating hormone (TSH) levels; and cervical cancer screening. Testing for *Chlamydia trachomatis* should be considered, especially in patients at high risk of infection (see Box 2). Ovulatory status usually can be determined by the presence of cyclic menses.

A CBC will indicate whether the patient has anemia or thrombocytopenic bleeding. The onset of heavy menses at menarche is often the first sign of von Willebrand disease. In all adolescents with heavy menstrual bleeding and adult patients with a positive screening history for a bleeding disorder, laboratory testing is indicated. Initial tests should include a CBC with platelets, prothrombin time, and partial thromboplastin time (fibrinogen or thrombin time are optional); bleeding time is neither sensitive nor specific, and is not indicated (14). Depending on the results of the initial tests, or if a patient's medical history is suggestive of an underlying bleeding condition, specific tests for von Willebrand disease or other coagulopathies may be indicated, including von Willebrand–ristocetin cofactor activity, von Willebrand factor antigen, and factor VIII (14, 20–23).

Hypothyroidism and hyperthyroidism are associated with AUB, although hypothyroidism is more common (24). Subclinical hyperthyroidism may be associated with AUB. In a study of apparently euthyroid women, those with heavy menstrual bleeding had significantly decreased levels of TSH and increased levels of total triiodothyronine, free triiodothyronine, free thyroxine, and total thyroxine as compared with normally menstruating women (25). Screening for thyroid disease with TSH level measurement in women with AUB is reasonable and inexpensive.

Imaging Techniques

The primary imaging test of the uterus for the evaluation of AUB is transvaginal ultrasonography. If transvaginal ultrasonographic images are not adequate or further evaluation of the cavity is necessary, then sonohysterography (also called saline infusion sonohysterography) or hysteroscopy (preferably in the office setting) is recommended (26). Magnetic resonance imaging is not a primary imaging modality for AUB. In adolescents, transabdominal ultrasonography may be more appropriate than transvaginal ultrasonography for evaluation.

Age-Based Common Differential Diagnosis

13–18 Years

In adolescents, AUB most frequently occurs as a result of persistent anovulation due to the immaturity or dysregulation of the hypothalamic–pituitary–ovarian axis and represents normal physiology (27). Abnormal uterine bleeding in adolescents also may be due to hormonal contraceptive use, pregnancy, pelvic infection, coagulopathies, or tumors (28). As many as 19% of adolescents with AUB who require hospitalization may have an underlying coagulopathy (29, 30), which emphasizes the importance of screening for coagulation disorders in these patients.

19–39 Years

Abnormal uterine bleeding most frequently occurs in women aged 19–39 years as a result of pregnancy, structural lesions (eg, leiomyomas or polyps), anovulatory cycles (eg, PCOS), use of hormonal contraception, and endometrial hyperplasia. Endometrial cancer is less common but may occur in this age group (31).

40 Years to Menopause

In women aged 40 years to menopause, abnormal uterine bleeding may be due to anovulatory bleeding, which represents normal physiology in response to declining ovarian function. It also may be due to endometrial hyperplasia or carcinoma, endometrial atrophy, and leiomyomas.

Clinical Considerations and Recommendations

When is imaging indicated in reproductive-aged women?

The literature is unclear as to when evaluation with imaging is indicated. Any patient with an abnormal physical examination, such as an enlarged or globular uterus on bimanual examination, should undergo transvaginal ultrasonography to evaluate for myomas and adenomyosis. When symptoms persist despite treatment in the setting of a normal pelvic examination, further evaluation is indicated with transvaginal ultrasonography, or biopsy, or both, if not already performed (see Fig. 2). When there is clinical suspicion for endometrial polyps or submucosal leiomyomas, sonohysterography or hysteroscopy will enable better detection of lesions. The decision to perform an imaging examination should be based on the clinical judgment of the health care provider with consideration of the cost and benefit to the patient (32). Measurement of endometrial thickness in premenopausal women is not helpful in the evaluation of AUB.

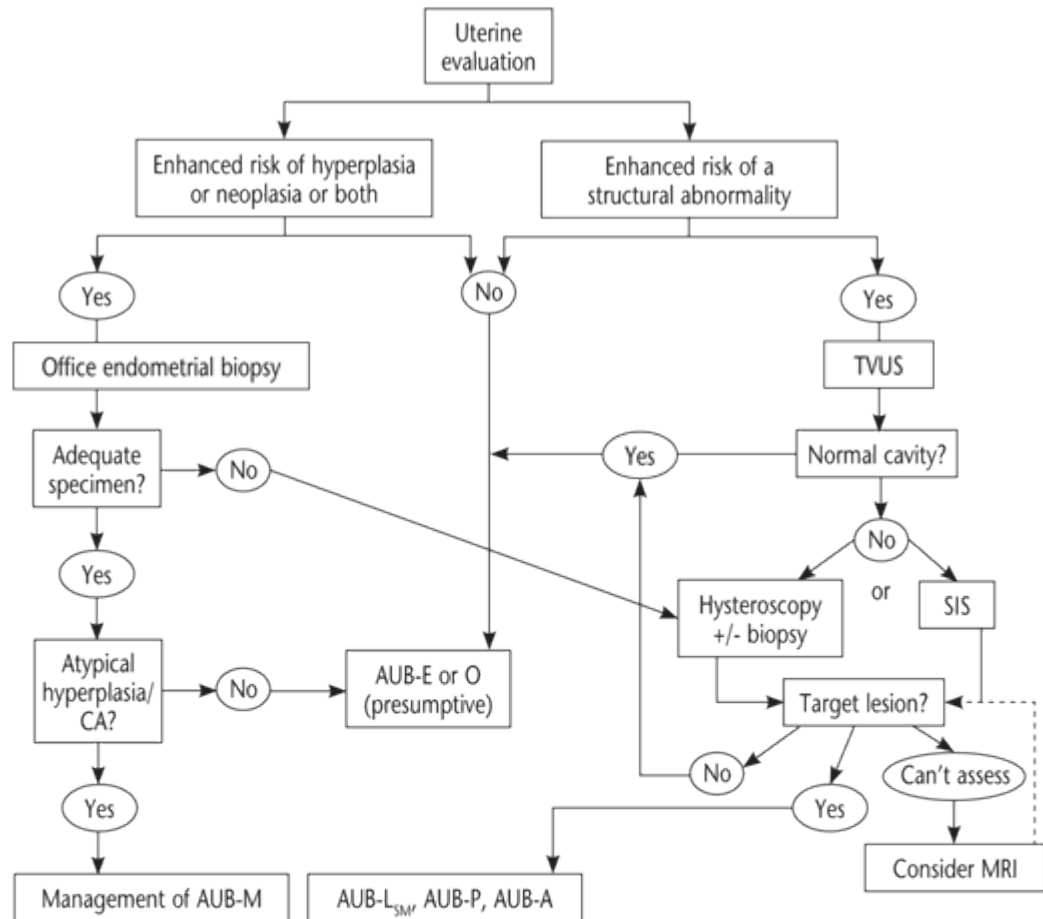


Fig. 2. Uterine evaluation. The uterine evaluation is, in part, guided by the medial history and other elements of the clinical situation, such as patient age, presence of an apparent chronic ovulatory disorder, or presence of other risk factors for endometrial hyperplasia or malignancy. For those at increased risk, endometrial biopsy is probably warranted. If there is a risk of structural anomaly, particularly if previous medical therapy has been unsuccessful, evaluation of the uterus should include imaging, at least with a screening transvaginal ultrasonography. Unless the ultrasound image indicates a normal endometrial cavity, it will be necessary to use either or both hysteroscopy and sonohysterography to determine whether target lesions are present. Such an approach is also desirable if endometrial sampling has not provided an adequate specimen. Uncommonly, these measures are inconclusive or, in the instance of virginal girls and women, not feasible outside of an anesthetized environment. In these instances, magnetic resonance imaging may be of value, if available. Abbreviations: AUB, abnormal uterine bleeding; AUB-P, polyp; AUB-A, adenomyosis; AUB-L_{SM}, leiomyoma submucosal; AUB-M, malignancy and hyperplasia; AUB-O, ovulatory dysfunction; AUB-E, endometrial; CA, carcinoma; MRI, magnetic resonance imaging; SIS, sonohysterography; TVUS, transvaginal ultrasonography. Reprinted from Munro MG. Abnormal Uterine Bleeding. Cambridge: Cambridge University Press; 2010.

How do transvaginal ultrasonography, sonohysterography, and magnetic resonance imaging compare in the assessment of uterine abnormalities?

Transvaginal ultrasonography is useful as a screening test to assess the endometrial cavity for leiomyomas and polyps. Although transvaginal ultrasonography is helpful for evaluating the myometrium itself, its sensitivity and specificity for evaluating intracavitary pathology are only 56% and 73%, respectively (33).

Substantial evidence exists to indicate that sonohysterography is superior to transvaginal ultrasonography in the detection of intracavitary lesions, such as polyps and submucosal leiomyomas (33–41). Only sonohysterography can distinguish between focal versus uniform thickening of the endometrium and structural abnormalities. A localized thickening of the endometrium may not yield adequate sampling with an endometrial biopsy.

Compared with transvaginal ultrasonography, sonohysterography also provides better information on the size and location of cavitory abnormalities (38). In a study that compared the accuracy of several diagnostic modalities, sonohysterography was as effective as hysteroscopy in detecting structural versus histopathologic abnormalities (33). In a large meta-analysis, the presence of intrauterine abnormalities in women with AUB was 46.6% (42). There are some data that indicate that three-dimensional sonohysterography may be more accurate than two-dimensional sonohysterography in determining the size and depth of myometrial invasion of submucosal leiomyomas, which may help predict the success of hysteroscopic resection (43, 44). However, there is insufficient evidence to recommend routine three-dimensional ultrasonography in the evaluation of AUB.

Routine use of magnetic resonance imaging (MRI) in the evaluation of AUB is not recommended. However, MRI may be useful to guide the treatment of myomas, particularly when the uterus is enlarged, contains multiple myomas, or precise myoma mapping is of clinical importance. However, the benefits and costs to the patient must be weighed when considering its use. The superior sensitivity of MRI may be useful when myomectomy is planned, before uterine artery embolization, for the detection of adenomyomas, and before focused ultrasound treatment (45–47).

How is ultrasonographic measurement of endometrial thickness useful in the evaluation of abnormal uterine bleeding in various age groups?

Ultrasonographic measurement of endometrial thickness is of limited value in detecting benign abnormalities in the premenopausal woman as compared with its ability to exclude malignancy in the postmenopausal woman (48–50). There are insufficient data to support the use of endometrial thickness in the evaluation of AUB in women of reproductive age who are at low risk. Endometrial thickness varies throughout the menstrual cycle in response to hormonal changes, making its diagnostic value in premenopausal women less useful.

When is endometrial tissue sampling indicated in patients with abnormal uterine bleeding and how should it be performed?

The primary role of endometrial sampling in patients with AUB is to determine whether carcinoma or premalignant lesions are present, although other pathology related to bleeding may be found. Endometrial tissue sampling should be performed in patients with AUB who are older than 45 years as a first-line test (see Fig. 2). Endometrial sampling also should be performed in patients younger than 45 years with a history of unopposed estrogen exposure (such as seen in obesity or PCOS), failed medical management, and persistent AUB (3).

An office endometrial biopsy is the first-line procedure for tissue sampling in the evaluation of patients with AUB. Endometrial sampling may be performed with a variety of office aspirators, office or inpatient hysteroscopy, or by dilation and curettage. A systematic review showed that endometrial biopsy has high overall accuracy in diagnosing endometrial cancer when an adequate specimen is obtained and when the endometrial process is global. If the cancer occupies less than 50% of the surface area of the endometrial cavity, the cancer can be missed by a blind endometrial biopsy (51). Further, the results showed that a positive test result is more accurate for ruling in disease than a negative test result is for ruling it out: the posttest probability of endometrial cancer was 81.7% (95% confidence interval, 59.7–92.9%) for a positive test result and 0.9% (95% confidence interval, 0.4–2.4%) for a negative test result (52). Therefore, these tests are only an endpoint when they reveal cancer or atypical complex hyperplasia. Persistent bleeding with a previous benign pathology, such as proliferative endometrium, requires further testing to rule out nonfocal endometrial pathology or a structural pathology, such as a polyp or leiomyoma. Other evaluation methods, such as transvaginal ultrasonography, sonohysterography, or office hysteroscopy also may be necessary when the endometrial biopsy is insufficient, nondiagnostic, or cannot be performed.

Hysteroscopy allows direct visualization of endometrial cavity abnormalities and the ability to take directed biopsies (26). Hysteroscopy is highly accurate in diagnosing endometrial cancer but less useful for detecting hyperplasia (53). Hysteroscopy may be performed in an office setting or in the operating room, with office hysteroscopy being less expensive, more convenient for the physician and patient, and offering faster recovery and less time off work for the patient (54, 55). Performing hysteroscopy in the operating room has the advantages of general anesthetics and the ability to perform laparoscopy should complications arise. In a meta-analysis that evaluated the accuracy of diagnostic hysteroscopy compared with guided biopsy during hysteroscopy, operative hysteroscopy, or hysterectomy, diagnostic hysteroscopy had an overall success rate of 96.6% (standard deviation, 5.2%; range, 83–100%), and abnormalities were found in 46.6% of premenopausal and postmenopausal women with AUB (42).

What tests are useful for diagnosing adenomyosis?

Adenomyosis can be diagnosed with transvaginal ultrasonography or MRI and is definitively diagnosed by histopathology. Ultrasonographic findings that support a diagnosis of adenomyosis include heterogeneous myometrium, myometrial cysts, asymmetric myometrial thickness, and subendometrial echogenic linear striations (56–60). Adenomyosis is best visualized with MRI using T2-weighted images (61, 62). The incidence of asymptomatic adenomyosis found incidentally on imaging studies in women has not been established. In studies that compared the effectiveness of transvaginal ultrasonography and MRI for the diagnosis of adenomyosis, MRI has been shown to be somewhere between equal to and superior (61, 63–66). The discrepancies in studies comparing the two modalities may be due to different diagnostic criteria for adenomyosis, varying quality of ultrasound machines over the time spans of the studies, and the experience of the radiologists in diagnosing adenomyosis. Transvaginal ultrasonography may perform less well in the presence of an enlarged uterus or with coexisting myomas (37, 65, 67). These factors and the expense of MRI have led some experts to recommend transvaginal ultrasonography as the initial screening test for AUB and MRI as a second-line test to be used when the

diagnosis is inconclusive, when further delineation would affect patient management, or when coexisting uterine myomas are suspected (59, 60, 62, 65, 67–70).

At what point in the evaluation is therapy appropriate?

In a patient without enhanced risk of endometrial hyperplasia, neoplasia, or structural abnormalities, such as adolescents, a trial of therapy is appropriate. For those at increased risk, such as patients with genetic risk factors for endometrial cancer, patients older than 45 years, or patients whose prolonged anovulatory cycles are associated with unopposed estrogen, initiation of therapy is appropriate after a complete diagnostic evaluation has been completed (see Fig. 2). Persistent bleeding despite therapy requires further evaluation. An appropriate trial of therapy will depend on the cause of the abnormal bleeding, the risks and benefits of the therapy, the costs to the patient, and the patient's own desire. Many causes of abnormal bleeding are amenable to medical management with nonsteroidal antiinflammatory drugs, progestins, combination oral contraceptives, a levonorgestrel intrauterine device, or tranexamic acid. For anatomic causes of abnormal uterine bleeding, such as uterine myomas or polyps, surgery may be indicated. Endometrial ablation and resection are minimally invasive surgical options to control bleeding in women who have completed childbearing (71).

Summary of Recommendations and Conclusions

The following recommendations and conclusions are based on good and consistent scientific evidence (Level A):

Substantial evidence exists to indicate that sonohysterography is superior to transvaginal ultrasonography in the detection of intracavitary lesions, such as polyps and submucosal leiomyomas.

In all adolescents with heavy menstrual bleeding and adult patients with a positive screening history for a bleeding disorder, laboratory testing is indicated. Initial tests should include a CBC with platelets, prothrombin time, and partial thromboplastin time (fibrinogen or thrombin time are optional); bleeding time is neither sensitive nor specific and is not indicated.

The following recommendations and conclusions are based on limited or inconsistent scientific evidence (Level B):

Testing for *Chlamydia trachomatis* should be considered, especially in patients at high risk of infection.

Hypothyroidism and hyperthyroidism are associated with AUB. Screening for thyroid disease with TSH level measurement in women with AUB is reasonable and inexpensive.

The following recommendations and conclusions are based primarily on consensus and expert opinion (Level C):

Endometrial tissue sampling should be performed in patients with AUB who are older than 45 years as a first-line test (see Fig. 2).

The American College of Obstetricians and Gynecologists supports the adoption of the PALM–COEIN nomenclature system developed by FIGO to standardize the terminology used to describe AUB.

Some experts recommend transvaginal ultrasonography as the initial screening test for AUB and MRI as a second-line test to be used when the diagnosis is inconclusive, when further delineation would affect patient management, or when coexisting uterine myomas are suspected.

MRI may be useful to guide the treatment of myomas, particularly when the uterus is enlarged, contains multiple myomas, or precise myoma mapping is of clinical importance. However, the benefits and costs to the patient must be weighed when considering its use.

Persistent bleeding with a previous benign pathology, such as proliferative endometrium, requires further testing to rule out nonfocal endometrial pathology or a structural pathology, such as a polyp or leiomyoma.

References

Spencer CP, Whitehead MI. Endometrial assessment revisited. *Br J Obstet Gynaecol* 1999;106:623–32. (Level III) [PubMed] ⇐

Fraser IS, Critchley HO, Munro MG, Broder M. A process designed to lead to international agreement on terminologies and definitions used to describe abnormalities of menstrual bleeding. Writing Group for this Menstrual Agreement Process [published erratum appears in *Fertil Steril* 2007;88:538]. *Fertil Steril* 2007;87:466–76. (Level III) [PubMed] [Full Text] ⇐

Munro MG, Critchley HO, Broder MS, Fraser IS. FIGO classification system (PALM–COEIN) for causes of abnormal uterine bleeding in nongravid women of reproductive age. FIGO Working Group on Menstrual Disorders. *Int J Gynaecol Obstet* 2011;113:3–13. (Level III) [PubMed] [Full Text] ⇐

Livingstone M, Fraser IS. Mechanisms of abnormal uterine bleeding. *Hum Reprod Update* 2002;8:60–7. (Level III) [PubMed] [Full Text] ⇐

Smith SK, Abel MH, Kelly RW, Baird DT. A role for prostacyclin (PGi2) in excessive menstrual bleeding. *Lancet* 1981;1:522–4. (Level II-3) [PubMed] ⇐

Adelantado JM, Rees MC, Lopez Bernal A, Turnbull AC. Increased uterine prostaglandin E receptors in menorrhagic women. *Br J Obstet Gynaecol* 1988;95:162–5. (Level III) [PubMed] ⇐

Smith SK, Abel MH, Kelly RW, Baird DT. Prostaglandin synthesis in the endometrium of women with ovular dysfunctional uterine bleeding. *Br J Obstet Gynaecol* 1981;88:434–42. (Level III) [PubMed] ⇐

Dockeray CJ, Sheppard BL, Daly L, Bonnar J. The fibrinolytic enzyme system in normal menstruation and excessive uterine bleeding and the effect of tranexamic acid. *Eur J Obstet Gynecol Reprod Biol* 1987;24:309–18. (Level II-3) [PubMed] ⇐

Gleeson N, Devitt M, Sheppard BL, Bonnar J. Endometrial fibrinolytic enzymes in women with normal menstruation and dysfunctional uterine bleeding. *Br J Obstet Gynaecol* 1993;100:768–71. (Level II-3) [PubMed] ⇐

James AH. More than menorrhagia: a review of the obstetric and gynaecological manifestations of bleeding disorders. *Haemophilia* 2005;11:295–307. (Level III) [PubMed] ⇐

Shankar M, Lee CA, Sabin CA, Economides DL, Kadir RA. von Willebrand disease in women with menorrhagia: a systematic review. *BJOG* 2004;111:734–40. (Level III) [PubMed] [Full Text] ⇐

Dilley A, Drews C, Miller C, Lally C, Austin H, Ramaswamy D, et al. von Willebrand disease and other inherited bleeding disorders in women with diagnosed menorrhagia. *Obstet Gynecol* 2001;97:630–6. (Level II-3) [PubMed] [Obstetrics & Gynecology] ⇐

Kadir RA, Economides DL, Sabin CA, Owens D, Lee CA. Frequency of inherited bleeding disorders in women with menorrhagia. *Lancet* 1998;351:485–9. (Level II-3) [PubMed] [Full Text] ⇐

National Heart, Lung, and Blood Institute. The diagnosis, evaluation, and management of von Willebrand Disease. NIH Publication No. 08-5832. Bethesda (MD): NHLBI; 2007. Available at: <http://www.nhlbi.nih.gov/guidelines/vwd/vwd.pdf>. Retrieved February 15, 2012. (Level III) ⇐

James AH, Manco–Johnson MJ, Yawn BP, Dietrich JE, Nichols WL. Von Willebrand disease: key points from the 2008 National Heart, Lung, and Blood Institute guidelines. *Obstet Gynecol* 2009;114:674–8. (Level III) [PubMed] [Obstetrics & Gynecology] ⇐

Basila D, Yuan CS. Effects of dietary supplements on coagulation and platelet function. *Thromb Res* 2005;117:49–53; discussion 65–7. (Level II-3) [PubMed] ⇐

Wittkowsky AK. A systematic review and inventory of supplement effects on warfarin and other anticoagulants. *Thromb Res* 2005;117:81–6; discussion 113–5. (Level III) [PubMed] ⇐

Valente MJ, Abramson N. Easy bruisability. *South Med J* 2006;99:366–70. (Level III) [PubMed] ⇐

Kirtava A, Drews C, Lally C, Dilley A, Evatt B. Medical, reproductive and psychosocial experiences of women diagnosed with von Willebrand’s disease receiving care in haemophilia treatment centres: a case-control study. *Haemophilia* 2003;9:292–7. (Level II-3) [PubMed] ⇐

Kouides PA. Current understanding of von Willebrand’s disease in women—some answers, more questions. *Haemophilia* 2006;12(suppl 3):143–51. (Level III) [PubMed] ⇐

Philipp CS, Faiz A, Dowling NF, Beckman M, Owens S, Ayers C, et al. Development of a screening tool for identifying women with menorrhagia for hemostatic evaluation. *Am J Obstet Gynecol* 2008;198:163.e1,163.e8. (Level II-3) [PubMed] ⇐

Jennings I, Kitchen S, Woods TA, Preston FE. Laboratory performance of haemophilia centres in developing countries: 3 years' experience of the World Federation of Hemophilia External Quality Assessment Scheme. *Haemophilia* 1998;4:739–46. (Level II-3) [PubMed] ⇐

Foster PA. The reproductive health of women with von Willebrand Disease unresponsive to DDAVP: results of an international survey. On behalf of the Subcommittee on von Willebrand Factor of the Scientific and Standardization Committee of the ISTH. *Thromb Haemost* 1995;74:784–90. (Level II-3) [PubMed] ⇐

Krassas GE. Thyroid disease and female reproduction. *Fertil Steril* 2000;74:1063–70. (Level III) [PubMed] [Full Text] ⇐

Attia AH, Youssef D, Hassan N, El-Meligui M, Kamal M, Al-Inany H. Subclinical hyperthyroidism as a potential factor for dysfunctional uterine bleeding. *Gynecol Endocrinol* 2007;23:65–8. (Level II-3) [PubMed] [Full Text] ⇐

Hysteroscopy. Technology Assessment No. 7. American College of Obstetricians and Gynecologists. *Obstet Gynecol* 2011;117:1486–91. (Level III) [PubMed] [Obstetrics & Gynecology] ⇐

Menstruation in girls and adolescents: using the menstrual cycle as a vital sign. ACOG Committee Opinion No. 349. American College of Obstetricians and Gynecologists. *Obstet Gynecol* 2006;108:1323–8. (Level III) [PubMed] [Obstetrics & Gynecology] ⇐

Slap GB. Menstrual disorders in adolescence. *Best Pract Res Clin Obstet Gynaecol* 2003;17:75–92. (Level III) [PubMed] [Full Text] ⇐

Claessens EA, Cowell CA. Acute adolescent menorrhagia. *Am J Obstet Gynecol* 1981;139:277–80. (Level III) [PubMed] ⇐

Minjarez DA, Bradshaw KD. Abnormal uterine bleeding in adolescents. *Obstet Gynecol Clin North Am* 2000;27:63–78. (Level III) [PubMed] ⇐

Management of endometrial cancer. ACOG Practice Bulletin No. 65. American College of Obstetricians and Gynecologists. *Obstet Gynecol* 2005;106:413–25. (Level III) [PubMed] [Obstetrics & Gynecology] ⇐

The role of transvaginal ultrasonography in the evaluation of postmenopausal bleeding. ACOG Committee Opinion No. 440. American College of Obstetricians and Gynecologists. *Obstet Gynecol* 2009;114:409–11. (Level III) [Obstetrics & Gynecology] ⇐

Kelekci S, Kaya E, Alan M, Alan Y, Bilge U, Mollamahmutoglu L. Comparison of transvaginal sonography, saline infusion sonography, and office hysteroscopy in reproductive-aged women with or without abnormal uterine bleeding. *Fertil Steril* 2005;84:682–6. (Level II-3) [PubMed] [Full Text] ⇐

Alborzi S, Parsanezhad ME, Mahmoodian N, Alborzi S, Alborzi M. Sonohysterography versus transvaginal sonography for screening of patients with abnormal uterine bleeding. *Int J Gynaecol Obstet* 2007;96:20–3. (Level II-3) [PubMed] [Full Text] ⇐

Guven MA, Bese T, Demirkiran F. Comparison of hydrososonography and transvaginal ultrasonography in the detection of intracavitary pathologies in women with abnormal uterine bleeding. *Int J Gynecol Cancer* 2004;14:57–63. (Level II-3) [PubMed] ⇐

de Vries LD, Dijkhuizen FP, Mol BW, Brolmann HA, Moret E, Heintz AP. Comparison of transvaginal sonography, saline infusion sonography, and hysteroscopy in premenopausal women with abnormal uterine bleeding. *J Clin Ultrasound* 2000;28:217–23. (Level II-3) [PubMed] ⇐

Dueholm M, Forman A, Jensen ML, Laursen H, Kracht P. Transvaginal sonography combined with saline contrast sonohysterography in evaluating the uterine cavity in premenopausal patients with abnormal uterine bleeding. *Ultrasound Obstet Gynecol* 2001;18:54–61. (Level II-3) [PubMed] [Full Text] ⇐

Schwarzler P, Concin H, Bosch H, Berlinger A, Wohlgenannt K, Collins WP, et al. An evaluation of sonohysterography and diagnostic hysteroscopy for the assessment of intrauterine pathology. *Ultrasound Obstet Gynecol* 1998;11:337–42. (Level II-3) [PubMed] [Full Text] ⇐

Farquhar C, Ekeroma A, Furness S, Arroll B. A systematic review of transvaginal ultrasonography, sonohysterography and hysteroscopy for the investigation of abnormal uterine bleeding in premenopausal women. *Acta Obstet Gynecol Scand* 2003;82:493–504. (Level III) [PubMed] [Full Text] ⇐

Botsis D, Papagianni V, Makrakis E, Aravantinos L, Creatsas G. Sonohysterography is superior to transvaginal sonography for the diagnostic approach of irregular uterine bleeding in women of reproductive age. *J Clin Ultrasound* 2006;34:434–9. (Level II-3) [PubMed] ⇐

Ryu JA, Kim B, Lee J, Kim S, Lee SH. Comparison of transvaginal ultrasonography with hydrososonography as a screening method in patients with abnormal uterine bleeding. *Korean J Radiol* 2004;5:39–46. (Level II-3) [PubMed] [Full Text] ⇐

van Dongen H, de Kroon CD, Jacobi CE, Trimpos JB, Jansen FW. Diagnostic hysteroscopy in abnormal uterine bleeding: a systematic review and meta-analysis. *BJOG* 2007;114:664–75. (Meta-analysis) [PubMed] [Full Text] ⇐

Salim R, Lee C, Davies A, Jolaoso B, Ofuasia E, Jurkovic D. A comparative study of three-dimensional saline infusion sonohysterography and diagnostic hysteroscopy for the classification of submucous fibroids. *Hum Reprod* 2005;20:253–7. (Level III) [PubMed] ⇐

de Kroon CD, Louwe LA, Trimpos JB, Jansen FW. The clinical value of 3-dimensional saline infusion sonography in addition to 2-dimensional saline infusion sonography in women with abnormal uterine bleeding: work in progress. *J Ultrasound Med* 2004;23:1433–40. (Level II-3) [PubMed] [Full Text] ⇐

Levens ED, Wesley R, Premkumar A, Blocker W, Nieman LK. Magnetic resonance imaging and transvaginal ultrasound for determining fibroid burden: implications for research and clinical care. *Am J Obstet Gynecol* 2009;200:537.e1–537.e7. (Level II-3) [PubMed] [Full Text] ⇐

Dueholm M, Lundorf E, Hansen ES, Ledertoug S, Olesen F. Accuracy of magnetic resonance imaging and transvaginal ultrasonography in the diagnosis, mapping, and measurement of uterine myomas. *Am J Obstet Gynecol* 2002;186:409–15. (Level II-3) [PubMed] ⇐

Zawin M, McCarthy S, Scoutt LM, Comite F. High-field MRI and US evaluation of the pelvis in women with leiomyomas. *Magn Reson Imaging* 1990;8:371–6. (Level III) [PubMed] ⇐

Dueholm M, Jensen ML, Laursen H, Kracht P. Can the endometrial thickness as measured by transvaginal sonography be used to exclude polyps or hyperplasia in pre-menopausal patients with abnormal uterine bleeding? *Acta Obstet Gynecol Scand* 2001;80:645–51. (Level II-3) [PubMed] [Full Text] ⇐

Breitkopf DM, Frederickson RA, Snyder RR. Detection of benign endometrial masses by endometrial stripe measurement in premenopausal women. *Obstet Gynecol* 2004;104:120–5. (Level II-3) [PubMed] [Obstetrics & Gynecology] ⇐

Dijkhuizen FP, De Vries LD, Mol BW, Brolmann HA, Peters HM, Moret E, et al. Comparison of transvaginal ultrasonography and saline infusion sonography for the detection of intracavitary abnormalities in premenopausal women. *Ultrasound Obstet Gynecol* 2000;15:372–6. (Level II-3) [PubMed] [Full Text] ⇐

Guido RS, Kanbour-Shakir A, Rulin MC, Christopherson WA. Pipelle endometrial sampling. Sensitivity in the detection of endometrial cancer. *J Reprod Med* 1995;40:553–5. (Level II-3) [PubMed] ⇐

Clark TJ, Mann CH, Shah N, Khan KS, Song F, Gupta JK. Accuracy of outpatient endometrial biopsy in the diagnosis of endometrial cancer: a systematic quantitative review. *BJOG* 2002;109:313–21. (Meta-analysis) [PubMed] [Full Text] ⇐

Clark TJ, Voit D, Gupta JK, Hyde C, Song F, Khan KS. Accuracy of hysteroscopy in the diagnosis of endometrial cancer and hyperplasia: a systematic quantitative review. *JAMA* 2002;288:1610–21. (Meta-analysis) [PubMed] ⇐

Marsh F, Kremer C, Duffy S. Delivering an effective outpatient service in gynaecology. A randomised controlled trial analysing the cost of outpatient versus daycase hysteroscopy. *BJOG* 2004;111:243–8. (Cost-benefit analysis) [PubMed] [Full Text] ⇐

Hidlebaugh D. A comparison of clinical outcomes and cost of office versus hospital hysteroscopy. *J Am Assoc Gynecol Laparosc* 1996;4:39–45. (Level II-3) [PubMed] ⇐

Kepkep K, Tuncay YA, Goynumer G, Tatal E. Transvaginal sonography in the diagnosis of adenomyosis: which findings are most accurate? *Ultrasound Obstet Gynecol* 2007;30:341–5. (Level II-3) [PubMed] [Full Text] ⇐

Atri M, Reinhold C, Mehio AR, Chapman WB, Bret PM. Adenomyosis: US features with histologic correlation in an in-vitro study. *Radiology* 2000;215:783–90. (Level III) findings and diagnostic accuracy. *J Ultrasound Med* 2000;19:529–34; quiz 535–6. (Level III) [PubMed] [Full Text] ⇐

Bromley B, Shipp TD, Benacerraf B. Adenomyosis: sonographic findings and diagnostic accuracy. *J Ultrasound Med* 2000;19:529—34; quiz 535—6. (Level III) [PubMed] [Full Text]↔

Reinhold C, Atri M, Mehio A, Zakarian R, Aldis AE, Bret PM. Diffuse uterine adenomyosis: morphologic criteria and diagnostic accuracy of endovaginal sonography. *Radiology* 1995;197:609—14. (Level II-3) [PubMed]↔

Reinhold C, Tafazoli F, Mehio A, Wang L, Atri M, Siegelman ES, et al. Uterine adenomyosis: endovaginal US and MR imaging features with histopathologic correlation. *Radiographics* 1999;19:S147—60. (Level III) [PubMed] ↔

Reinhold C, McCarthy S, Bret PM, Mehio A, Atri M, Zakarian R, et al. Diffuse adenomyosis: comparison of endovaginal US and MR imaging with histopathologic correlation. *Radiology* 1996;199:151—8. (Level II-3) [PubMed] ↔

Dueholm M, Lundorf E. Transvaginal ultrasound or MRI for diagnosis of adenomyosis. *Curr Opin Obstet Gynecol* 2007;19:505—12. (Level III) [PubMed] ↔

Dueholm M, Lundorf E, Hansen ES, Sorensen JS, Ledertoug S, Olesen F. Magnetic resonance imaging and transvaginal ultrasonography for the diagnosis of adenomyosis. *Fertil Steril* 2001;76:588—94. (Level II-3) [PubMed] ↔

Levgur M. Diagnosis of adenomyosis: a review. *J Reprod Med* 2007;52:177—93. (Level III) [PubMed] [Full Text] ↔

Bazot M, Cortez A, Darai E, Rouger J, Chopier J, Antoine JM, et al. Ultrasonography compared with magnetic resonance imaging for the diagnosis of adenomyosis: correlation with histopathology. *Hum Reprod* 2001;16:2427—33. (Level II-3) [PubMed] ↔

Ascher SM, Arnold LL, Patt RH, Schrufer JJ, Bagley AS, Semelka RC, et al. Adenomyosis: prospective comparison of MR imaging and transvaginal sonography. *Radiology* 1994;190:803—6. (Level III) [PubMed] ↔

Bazot M, Darai E, Rouger J, Detchev R, Cortez A, Uzan S. Limitations of transvaginal sonography for the diagnosis of adenomyosis, with histopathological correlation. *Ultrasound Obstet Gynecol* 2002;20:605—11. (Level II-3) [PubMed] ↔

Moghadam R, Lathi RB, Shahmohamady B, Saberi NS, Nezhat CH, Nezhat F, et al. Predictive value of magnetic resonance imaging in differentiating between leiomyoma and adenomyosis. *JSLs* 2006;10:216—9. (Level II-3) [PubMed] [Full Text] ↔

Dueholm M. Transvaginal ultrasound for diagnosis of adenomyosis: a review. *Best Pract Res Clin Obstet Gynaecol* 2006;20:569—82. (Level III) [PubMed] [Full Text] ↔

Arnold LL, Ascher SM, Schrufer JJ, Simon JA. The nonsurgical diagnosis of adenomyosis. *Obstet Gynecol* 1995;86:461—5. (Level III) [PubMed] [Full Text] ↔

Endometrial ablation. ACOG Practice Bulletin No. 81. American College of Obstetricians and Gynecologists. Obstet Gynecol 2007;109:1233–48. (Level III) [PubMed] [Obstetrics & Gynecology] ⇐

The MEDLINE database, the Cochrane Library, ISSN 1099-3630

and the American College of Obstetricians and Gynecologists' own internal resources and documents were used to conduct a literature search to locate relevant articles published between January 1990 and November 2008. The search was restricted to articles published in the English language. Priority was given to articles reporting results of original research, although review articles and commentaries also were consulted. Abstracts of research presented at symposia and scientific conferences were not considered adequate for inclusion in this document. Guidelines published by organizations or institutions such as the National Institutes of Health and the American College of Obstetricians and Gynecologists were reviewed, and additional studies were located by reviewing bibliographies of identified articles. When reliable research was not available, expert opinions from obstetrician–gynecologists were used.

The American College of Obstetricians and Gynecologists
409 12th Street, SW, PO Box 96920, Washington, DC
20090-6920

Diagnosis of abnormal uterine bleeding in reproductive-aged women. Practice Bulletin No. 128. American College of Obstetricians and Gynecologists. Obstet Gynecol 2012;120:197–206.

Studies were reviewed and evaluated for quality according to the method outlined by the U.S. Preventive Services Task Force:

I Evidence obtained from at least one properly designed randomized controlled trial.

II-1 Evidence obtained from well-designed controlled trials without randomization.

II-2 Evidence obtained from well-designed cohort or case–control analytic studies, preferably from more than one center or research group.

II-3 Evidence obtained from multiple time

series with or without the intervention. Dramatic results in uncontrolled experiments also could be regarded as this type of evidence.

III Opinions of respected authorities, based on clinical experience, descriptive studies, or reports of expert committees.

Based on the highest level of evidence found in the data, recommendations are provided and graded according to the following categories:

Level A—Recommendations are based on good and consistent scientific evidence.

Level B—Recommendations are based on limited or inconsistent scientific evidence.

Level C—Recommendations are based primarily on consensus and expert opinion.